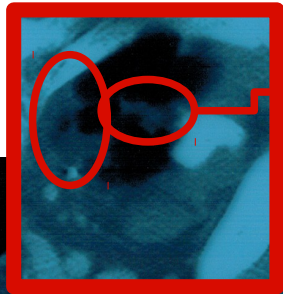


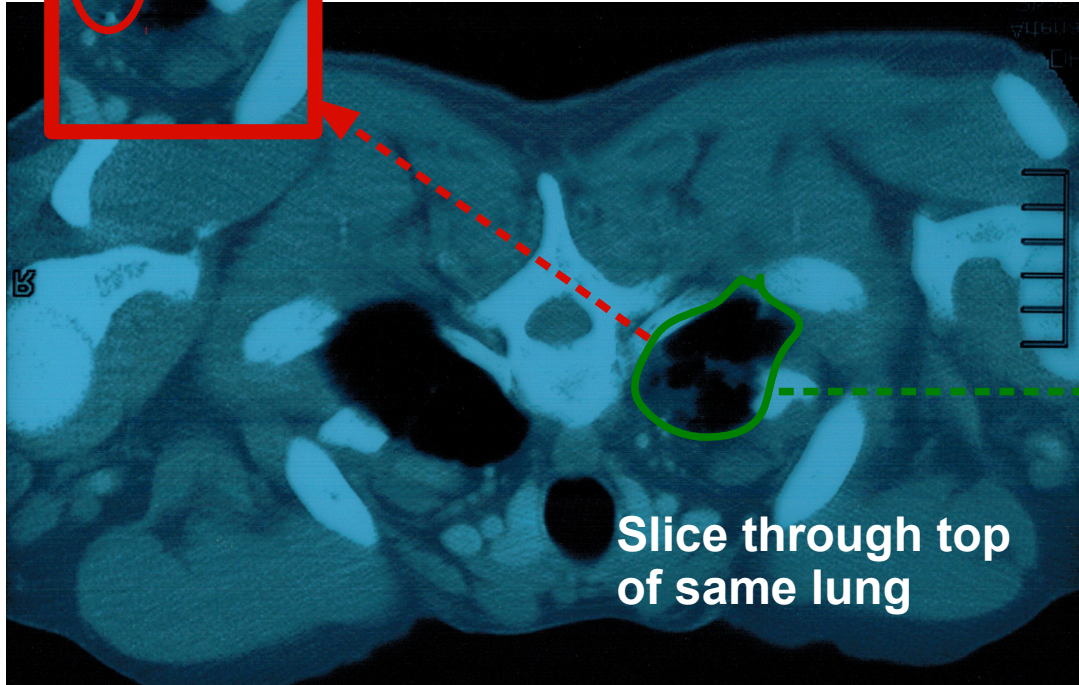


Reversal of chronic lung scarring from Tuberculosis infection

Detail

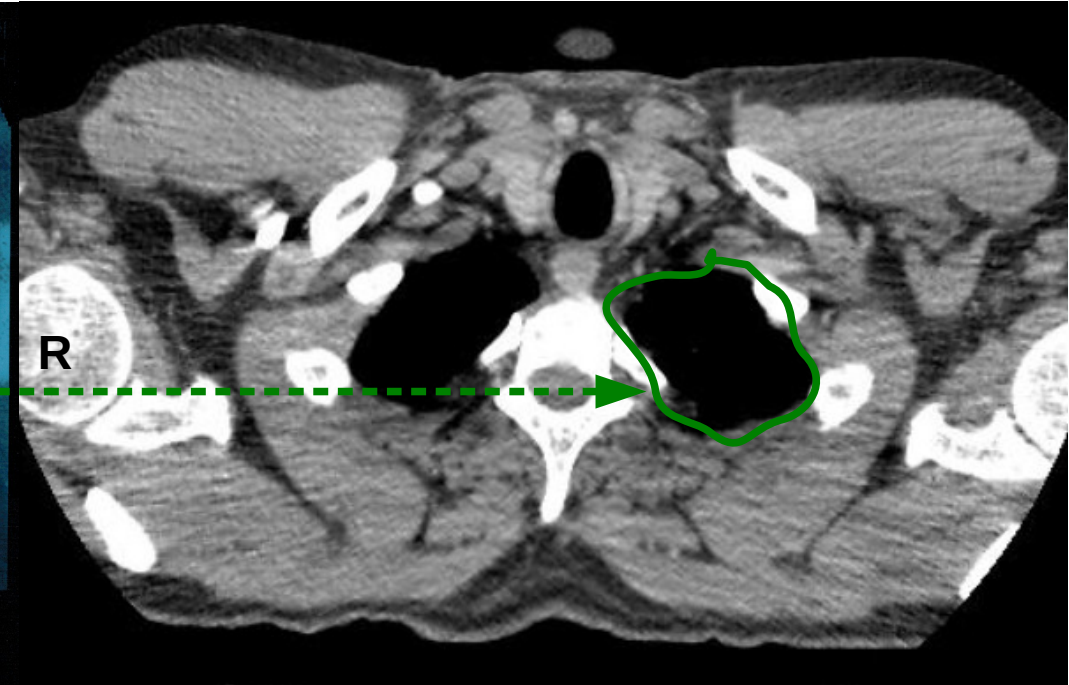


Paler 'solid' patches are scar tissue.



Slice through top of same lung

2009



2013

Image has been flipped vertically during scan