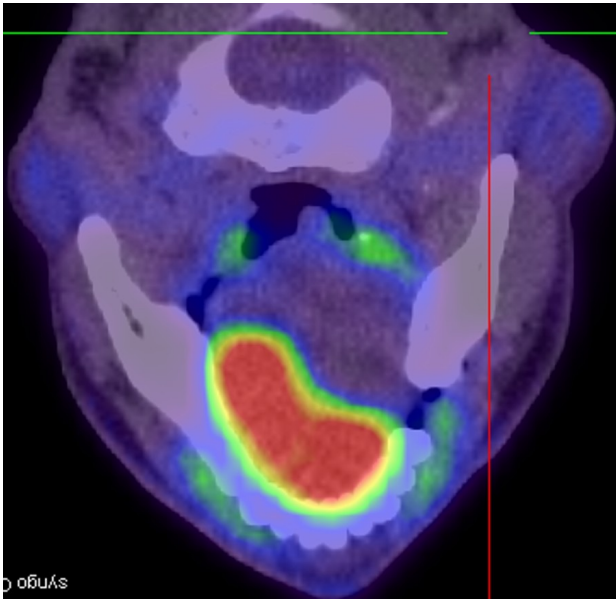
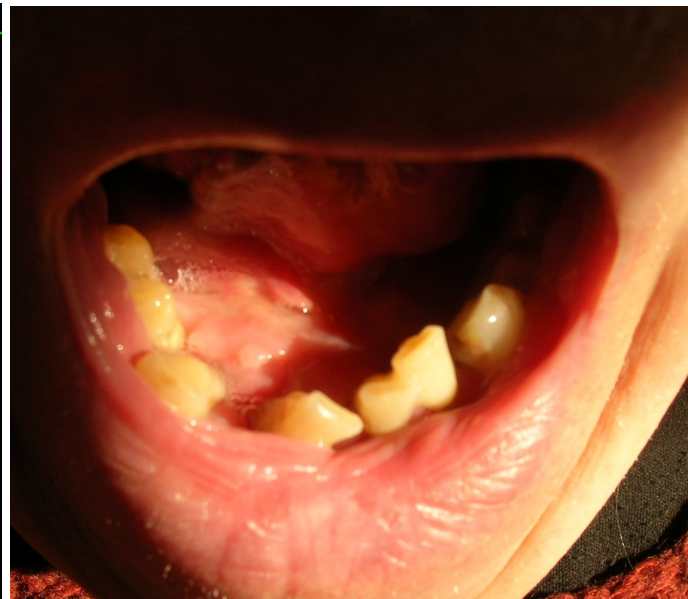



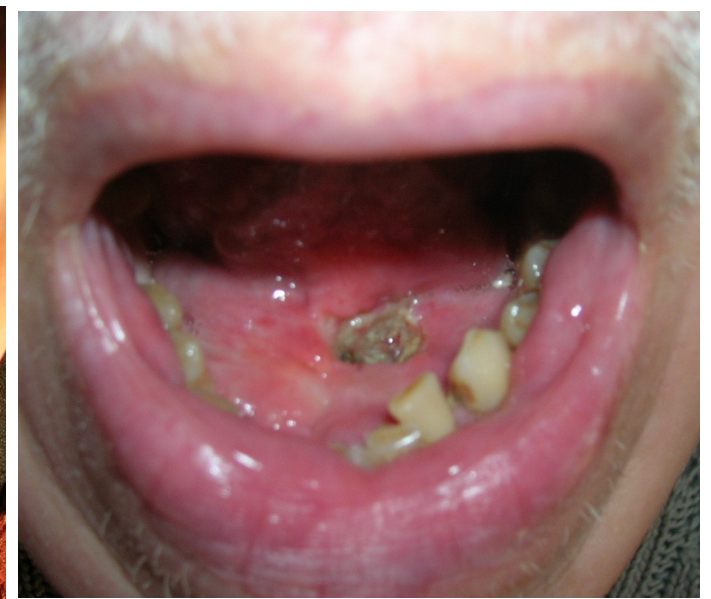Complete reversal (disappearance) of chemotherapy-resistant 5cm Stage IV oral squamous cell carcinoma (cancer)



August 2009



July 2010



September 2010